

## Clinicopathological Session for the Purpose of a Case of Chronic Meningoencephalitis by *Coccidioides Immitis*

Dr. Gabriel Miranda Nava

Chief of Neurology of the Hospital Center of the Presidential General Staff. Mexico City.

**\*Corresponding Author:** Dr. Gabriel Miranda Nava, Chief of Neurology of the Hospital Center of the Presidential General Staff. Mexico City.

### ABSTRACT

Chronic meningoencephalitis is a syndrome that corresponds to about 10% of meningeal tables. It is a condition with many causes and therefore constitutes a real diagnostic challenge. Among the most common causes include: infectious agents, toxic, inflammatory, neoplastic, auto immune and idiopathic. These disorders require a battery of extensive and expensive studies, although it is not always possible to establish the diagnosis. Cerebral and meningeal biopsies play an important role in examining these patients.

A detailed and careful history and examination is required along with CSF parameters to guide a clinician towards the aetiology of the problem. Neuroimaging modalities have become a useful tool in the quest for a diagnosis in such cases. Treatment of chronic meningitis depends on the underlying cause. Once a specific cause has been established, appropriate targeted therapy is initiated. When the cause is unknown, a decision must be made whether to employ empiric therapy while the diagnostic evaluation is ongoing. We presents a case commented in clinical-pathologic session in Central Military Hospital, about an immunocompetent male patient, previously healthy manifesting clinical signs compatible with chronic meningoencephalitis, with a progressive and unfavorable course, in which, despite the imaging studies, laboratory and CSF, as well as empirical therapy management is becomes impossible to determine etiology. Finally neurococcidioidomycosis performed postmortem diagnosis by means of histopathological examination of brain tissue sections. Demonstrating the diagnostic difficulty that these paintings represent and the importance of early diagnosis when conditions favor it.

**Keywords:** Chronic meningoencephalitis, *coccidioides immitis*, neurococcidioidomycosis

### INTRODUCTION

Meningitis refers to an inflammatory process of leptomeninges and CSF within the subarachnoid space. Meningoencephalitis refers to inflammation of the meninges and cerebral parenchyma.<sup>1</sup> Chronic meningoencephalitis is a syndrome that corresponds to approximately 10% of meningeal symptoms. They share a clinic of insidious nature such as headache, behavioral alterations, compromise of consciousness, signs of focal neurological compromise and seizures, more encephalitic than meningitic, associated with moderate CSF pleocytosis composed of mononuclear cells or a mixture of polymorphonuclear cells and cells. mononuclear; the protein level is elevated, often markedly, and the glucose content is usually reduced or normal, the former in a picture that persists for at least 4 weeks.<sup>2</sup> The etiologies are diverse, both infectious (fungi, parasites and bacteria) and non-infectious

(exposure to chemicals), neoplastic, autoimmune and even idiopathic, so their syndromic study merits a series of CSF tests, bounded when possible for the clinic. In the absence of risk factors or clinically orienting in the etiological, in a subacute or chronic meningoencephalitis, evaluation of the CSF whose appearance is clear must include: cytochemical examination, Chinese ink stain and fungal culture, stain and culture for bacillus of koch, tests of cysticercosis, study of syphilis, adenosine deaminase and search for neoplastic cells. The lethality of these pictures will depend on the etiology, but it reaches 30%, in addition it has a high index of sequelae. In the clinical case that concerns us on this occasion, the clinical, laboratory and paraclinical lead us to a meningoencephalitis of fungal origin. In these, the brain is usually affected only at the end of the disease, where there is a haematogenous spread of the fungus, most often *Candida albicans*, *Mucor*, *Aspergillus fumigatus* and

*Cryptococcus neoformans*. In pathogenic endemic areas such as *Histoplasma capsulatum*, *Coccidioides immitis* and *Blastomyces dermatidis* can affect the CNS after a primary pulmonary or cutaneous infection.<sup>3</sup> *Coccidioidomycosis* (CM) is an endemic mycosis in some regions of the United States, in the Northwest and Northeast of Mexico. Mexico and in certain areas in Central and South America.<sup>4</sup> Extrapulmonary CM occurs in 1 of every 200 infected subjects; the most commonly affected sites are meninges, bones, joints, skin and soft tissues.<sup>6</sup> CM is the oldest systemic mycosis, <sup>7</sup> was first described in an Argentine soldier in 1892, reporting the case as mycosis fungoidea.<sup>8</sup> Meningitis is the most serious complication of this infection, with no specific treatment 100% of patients die.<sup>9</sup> The clinical case of immunocompetent patient, previously healthy, with manifestations of chronic meningitis, with cultures for bacteria and negative fungi is presented below in CSF, who despite treatment with azo compounds, died and after this histopathological diagnosis was made that reveals *Coccidioides immitis* as a causative agent, highlighting the diagnostic difficulty and the importance of early diagnosis when conditions favor it.

## CASE REPORT

It is a male patient, 33 years old, active military, original and resident of the city of Oaxaca.

He began his illness in November 2009, one month before his admission to the Regional

Military Hospital of Puebla (HMRP), with a clinical picture characterized by: intense headache, oppressive, predominantly frontal, which does not yield to the administration of analgesics, accompanied by nausea without reaching vomiting, disturbances of thinking with fluctuations in the course of the day, reduced ability to maintain or direct attention, disorganized thinking, even led to disciplinary problems.

He entered the HMRP on December 23 of the same year where he was approached by the Neurology and Psychiatry services. On admission with few data since indirect interrogation is performed, pathological and non-pathological personal history is unknown, the physical examination reveals: Glasgow 12/15, neck stiffness, kerning and brudzinski (+), fever of 38°C, acute confusional state with Incoherent verbal responses, alteration of critical judgment and reasoning, at 24 hrs generalized tonic-clonic seizures are added. Serology studies with V.I.H and V.D.R.L negative. Lumbar puncture: Colorless, appearance in rock water, Glucose 16 mg / dl, protein 158mg / dl, leukocytes 25, PMN 60%, mononuclear 40%, negative bacterial cultures. (Table 1.0) Hematic Biometry: Leukocytes 14,690 x10<sup>3</sup>, with neutrophilia, platelets 187,000. (Table 2.0) Blood chemistry: Glucose 120 mg / dl (Table 3.0). Chest x-ray, EGO and Uroculture without alterations. Cabinet: Skull CAT scan in simple and contrasted phase.

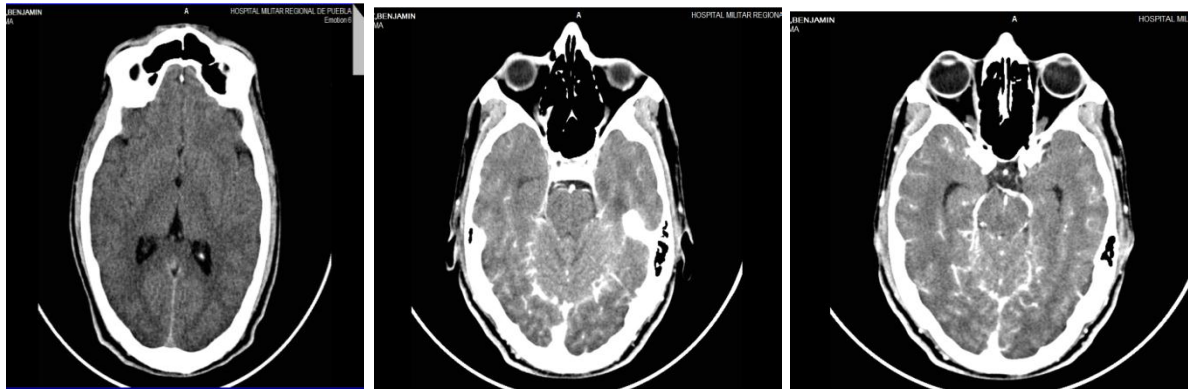**Table1.** Study of the CSF during the follow-up of the case.

CHARACTERISTIC	24.12.09	31.12.09	05.01.10
Appearance	Rock water	cloudy	Thick
Color	Colorless	Xanthochromic	Xanthochromic
Pressure			
Glucose	16 mg/dl	27 mg/dl	50 mg/dl
Proteins	158 mg/dl	190.4 mg/dl	
Chlorides		115 mEq/L	
Leukocytes	25	686	34
Polymorphonuclear	60%	85%	60%
Mononuclear	40%	15%	
LDH		105 UI/L	200 UI/L

**Table2.** Result of BH and QS during the follow-up of the case.

HEMATIC BIOMETRY		
PARAMETER	24.12.09	31.12.09
LEUCOCITS	14,690 X 10 <sup>3</sup>	15, 789 x10 <sup>3</sup>
NEUTROFILOS	83.9%	95%
LYMPHOCYTES	3.9%	3.4%
PLATELETS	187,000	92,000
BLOOD CHEMISTRY		

PARAMETER	24.12.09	31.12.09
GLUCOSE	120 mg/dl	127
CREATININ	0.6 mg/dl	
UREA	29 mg/dl	
SODIUM	134 mEq/L	155
POTASSIUM	4.2 mEq/L	4.22

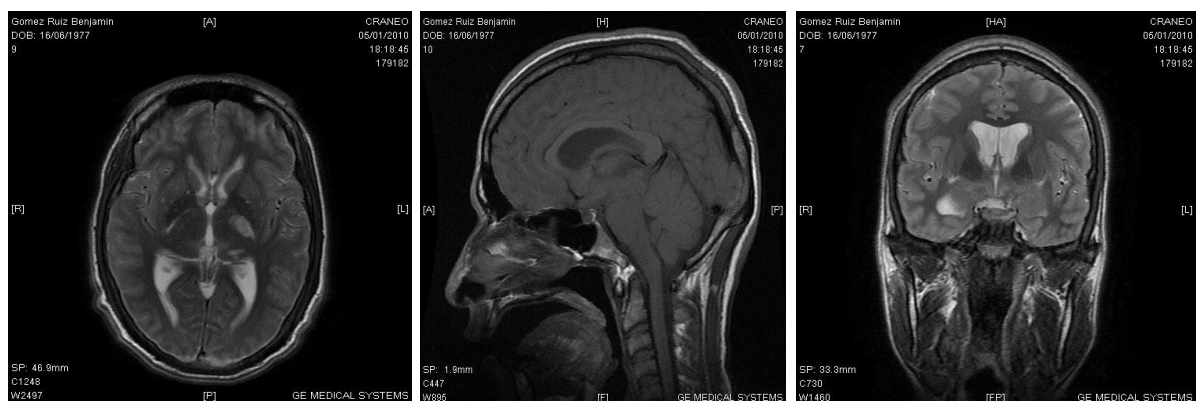


**Figure1.** Computed tomography of the skull. A. Simple phase B and C. Contrast phase where meningeal reinforcement is observed.

Empirical treatment is started with: Meropenem, cefotaxime, rifampin plus isoniazid, acyclovir, dexamethasone, B complex, parenteral fluids. It persists with fever, neurological deterioration and a psychiatric problem is ruled out, so that on December 31, 2009 it moves to the 3rd level of attention to the Central Military Hospital. It enters with the following clinical data: Disorientation, intense headache, throbbing, holocranana, accompanied by nausea and vomiting, fever of 38 °, confusional state with psychomotor agitation, vague, irrelevant and incoherent language, neck stiffness without finding other meningeal data. The CSF study gives the following data: xanthochromic appearance, thick, glucose 27 mg / dl, proteins

190.4 mg / dl, chlorides 115 mEq / L, leukocytes 686 with 85% PMN. BAAR, GRAM, KOH, Chinese ink and culture for fungi in Sabouraud negative medium. (Table 1.0)

Antifungal treatment is modified by initiating RIFATER, Vancomycin and Acyclovir are added. EEG shows generalized epileptiform discharges, which is why Valpróico Acid is started. January 2, 2010, fluconazole 400mg is added every 12 hrs intravenously. On January 5, MRI showed changes compatible with meningoencephalitis, cerebral edema and non-communicating hydrocephalus, acute ischemic events in the base ganglia and left side mesencephalon.



**Figure2.** Magnetic resonance image. A is observed. Axial slice in T2 sequence. Sagittal section in T1 sequence. C. Coronal section in T2 sequence.

7 of January, the Glasgow falls to 8/15, January 10 is glaring due to neurological deterioration and severe respiratory distress and enters intensive therapy, 11 of January a

ventriculostomy is performed to improve hydrocephalus, however it occurs with increased intracranial pressure and neurological deterioration, with lethargy and stupor. January

15 falls into cardiorespiratory arrest without success in the resuscitation maneuvers. On January 16, a histopathological study was performed, which reports: Meningitis with basal arachnoiditis, secondary hydrocephalus, vasculitis, multiple infarctions, parenchymal granulomas and thrombosis of the cavernous sinus.

## **DISCUSSION**

Coccidioidomycosis or San Joaquin Valley fever is a systemic mycosis caused by the dimorphic fungi *Coccidioides immitis* or *C. posadasii*, which despite being highly contagious, is not transmitted from person to person and its true incidence and prevalence is unknown. because it is not among the pathologies of mandatory reporting.

### **Epidemiology**

It is an endemic mycosis in some regions of the United States (California, Arizona, New Mexico and Texas), in the Northwest and Northeast of Mexico and in certain areas in Central and South America, 4 this dimorphic fungus that grows in layers of topsoil in semi-arid zones, 10 where a warm climate prevails, low altitude and little rain.

### **Pathophysiology**

In the aforementioned habitat develops as a mycelium (saprophytic form), these alternating mycelial cells undergo a process of autolysis and thinning of their cell walls, the remaining cells (arthroconidia) develop a hydrophobic outer layer which gives them the ability to remain viable for long periods of time and their fragile fixations become prone to separation by physical breakage or even by some turbulence of air, consequently, they are transmitted by the air in a form apt to be deposited in the lungs if inhaled. In the lungs the arthroconidia are remodeled into spherical cells (parasitic form) and lose their hydrophobic outer wall, divide, multiply and as they mature, they break to release viable endospores, which produce a chemotactic effect in neutrophils. The most common route of dissemination to the CNS is hematogenous, and it can also occur by contiguity in cases of cranial or vertebral osteomyelitis.

### **Clinical course**

The clinical picture is characterized by:

Headache

Neurological alterations.

Meningeal irritation data

Constitutional signs and symptoms

Other manifestations

The disease can affect individuals at any stage of life and often has an unfavorable evolution. However, males become infected more frequently, probably because of the relationship with occupational exposure to contaminated dust; however, they also have a greater tendency to spread, suggesting a genetic or hormonal component.<sup>11</sup>

### **Laboratory and Cabinet**

The red and white series do not usually undergo changes, however, in some cases leukocytosis with eosinophilia has been reported. Examination of cerebrospinal fluid usually reveals mononuclear pleocytosis, hypoglucorrhache, and protein elevation. In some cases, elevated CSF pressure has been reported. Approximately in 33% of the cases it is not possible to identify this agent despite the exhaustive analysis of the CSF and other possible causes outside the CNS. Some microorganisms that cause chronic meningitis take several weeks to grow in culture. Because extra pulmonary coccidioidomycosis is always secondary to dissemination from a primary pulmonary focus, chest x-rays should be performed, in which it is possible to find a frequently unilateral infiltrate with involvement of the upper lobes.<sup>12</sup>

### **Treatment**

Currently, triazole antifungals are the main drugs administered for the treatment of many cases of coccidiomycosis. Fluconazole has been shown to penetrate into the CSF, making it the azole compound most indicated for the treatment of coccidioid meningitis, these should be used with the minimum adult oral dose of 400mg / day that offers a response around the 70% This is an important difference with the standard treatment of intrathecal Amphotericin B, which was still common until a few years ago.<sup>13</sup> Currently, two new products of this category are posaconazole and voriconazole. However, given the scarce clinical data, the high cost and (especially in the case of voriconazole) the possible toxic effects, the drugs in question are reserved for cases that remain recalcitrant after treatment with fluconazole or itraconazole. The administration of triazoles in high doses can be teratogenic, so we can think of amphotericin B to treat coccidiomycosis in pregnant



women.<sup>14</sup> In addition to antifungal therapy to control meningeal inflammation, interventions for other manifestations are needed. Hydrocephalus usually does not respond to antifungal therapy and requires a CSF bypass procedure. Ventriculoperitoneal shunts become a conduit for *C. immitis* from the cerebrospinal space to the peritoneum, but usually do not produce clinically evident abdominal complications. Although the infection predominantly affects the basal meninges, intracerebral abscesses sometimes develop.<sup>15</sup> These lesions may require drainage or resection in addition to systemic mycotic treatment.

## CONCLUSIONS

The fact that coccidioidomycosis is now a newly emerging disease can be attributed to changes in both demography and contemporary medicine. First, the populations at risk of exposure are very expanded. The regions in which *C. immitis* is endemic, which were previously sparsely populated, now comprise major metropolitan centers. With this growth, tourism and the movement of people towards infected areas and from them have increased a lot. Second, an important stratum of the population has emerged with compromise of cellular immunity due to underlying diseases or immunosuppressive treatments to control other diseases.<sup>16</sup> However, due to its low frequency in immunocompetent patients, this diagnostic possibility may go unnoticed, and should be considered in endemic areas.

## REFERENCES

- [1] *Robbins & Cotran Pathologic Basis of Disease* 7<sup>th</sup> edition. pp1375-1376
- [2] Tratado de Neurología Clínica, Jorge Nogales GAETE 2005, pp 345-350.
- [3] Chronic meningitis, Shiraz E Medical Journal, vol. 1, No. 1, October 2009, Borhan Haghighi A.
- [4] Stevens DA. *Coccidioides immitis*. En: Mandell GL, Bennet JE, Dolin R, editores. Principles and practice of infectious diseases, 4<sup>th</sup> ed. New York: Churchill-Livingstone;1995. pp. 2365-2375
- [5] Zeppa M, Laorr A, Greenspan A, McGahan J, Steinbach L. Skeletal coccidioidomycosis: imaging findings in 19 patients. *Skeletal Radiol* 1996; 25: 337-43.
- [6] Crum NF, Lederman ER, Stafford CM, et al. Coccidioidomycosis: a descriptive survey of a reemerging disease: clinical characteristics and current controversies. *Medicine*. 2004;83:149-175.
- [7] Einstein HE, Jonhson RH. Coccidioidomycosis: new aspects of epidemiology and therapy. *Clin Infect Dis* 1993;16: 349-354
- [8] Posada A. Un Nuevo caso de micosis fungoidea con psorospemias. *Ann Círculo Médico Argentino* 1892; 15: 585-598.
- [9] Pappagianis D. *coccidioides immitis*. In: ajello L, Hay RJ. Microbiology and microbial infections vol 4.9<sup>th</sup>. Edic. Nueva York: Oxford University Press 2001: 357-72.
- [10] A Coccidioidomycosis Outbreak Following the Northridge, Calif, Earthquake. Eileen Schneider at cols. 1997; 277:904.
- [11] (Crum NF, Lederman ER, Stafford CM, Parrish JS, Wallace MR. Coccidioidomycosis: a descriptive survey of a reemerging disease. Clinical characteristics and current controversies. *Medicine* 2004;83:149-175.)
- [12] (Galgiani JN. Coccidioidomycosis. *West J Med* 1993;159:153-171.)
- [13] (Labadie EL, Hamilton RH. Survival improvement in coccidioidal meningitis by high-dose intrathecal amphotericin B. *Arch Intern Med*. 1986;146:2013-1018.)
- [14] (Harrison 1248-1249 tomo 2.)
- [15] (BaZuelos AF, Williams PL, Jonhson RH, et al. Central nervous system abscess due to coccidioides species. *Clin Infect Dis*. 1996; 22:240-250).
- [16] (Rutala PJ, Smith JW. Coccidioidomycosis in potentially compromised host: The effect of immunosuppressive therapy in dissemination. *Am J Med Sci*. 1978;275:238-295.)

**Citation:** Dr. Gabriel Miranda Nava, Clinicopathological Session for the Purpose of a Case of Chronic Meningoencephalitis by *Coccidioides Immitis*. *International Journal of Research Studies in Medical and Health Sciences*. 2018; 3(4):9-13.

**Copyright:** © 2018 Dr. Gabriel Miranda Nava. This is an open-access article distributed under the terms of the Creative Commons Attribution License, which permits unrestricted use, distribution, and reproduction in any medium, provided the original author and source are credited.